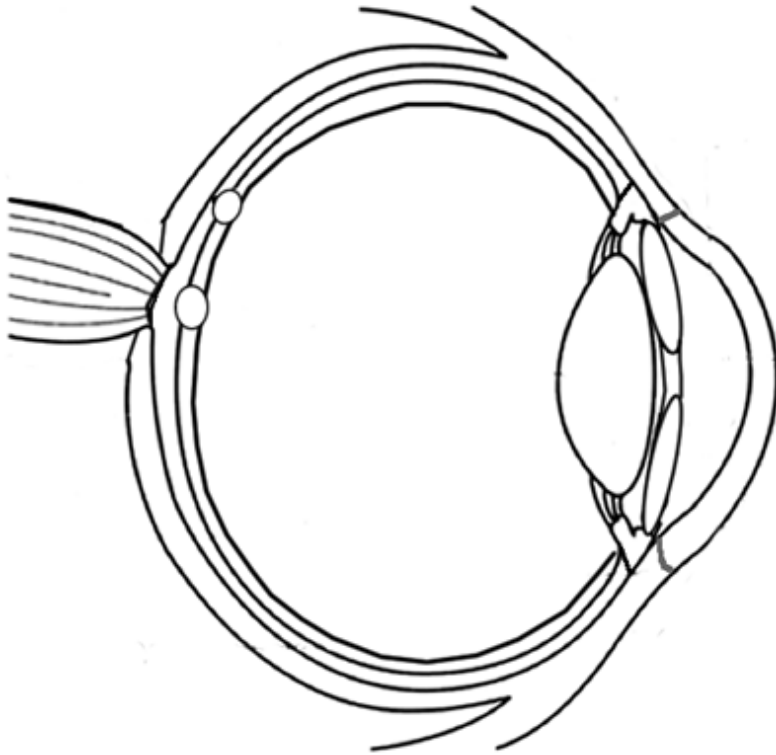
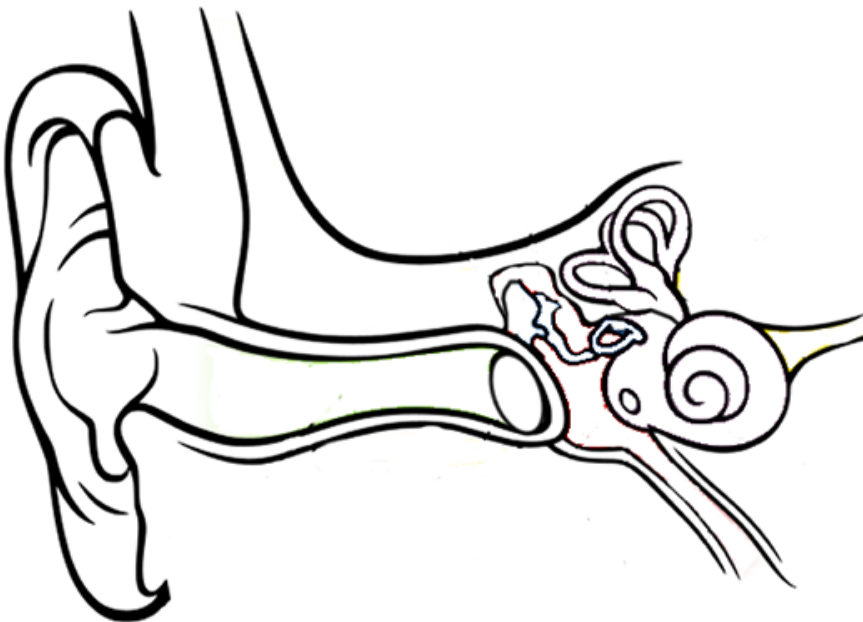


Anatomy of the Eye and Ear (Coloring)



- Optic Nerve (blue)
- Optic Disk (yellow)
- Fovea Centralis (gray)
- Vitreous Humor (pink)
- Aqueous Humor (yellow)
- Cornea (dark green)
- Pupil (black)
- Iris (brown)
- Ciliary Body (orange)
- Retina (blue)
- Lens (light blue)
- Sclera (light green)



- Pinna (brown)
- External Auditory Meatus (yellow)
- Tympanum (gray)
- Malleus (pink)
- Incus (purple)
- Stapes (black)
- Semicircular Canals (purple)
- Cochlea (red)
- Vestibulocochlear Nerve (blue)
- Round Window (orange)
- Tympanic Cavity (light blue)
- Eustachian Tube (green)