

6

The Muscular System

Muscles, the specialized tissues that facilitate body movement, make up about 40% of body weight. Most body muscle is the voluntary type, called skeletal muscle because it is attached to the bony skeleton. Skeletal muscle contributes to body contours and shape, and composes the organ system called the muscular system. These muscles allow you to grin, frown, run, swim, shake hands, swing a hammer, and to otherwise manipulate your environment. The balance of body muscle is smooth and cardiac muscles, which form the bulk of the walls of hollow organs and the heart. Smooth and cardiac muscles are involved in the transport of materials within the body.

Study activities in this chapter deal with microscopic and gross structure of muscle, identification of voluntary muscles, body movements, and important understandings of muscle physiology.

OVERVIEW OF MUSCLE TISSUES

1. Nine characteristics of muscle tissue are listed below and on page 90. Identify the muscle tissue type described by choosing the correct response(s) from the key choices. Enter the appropriate term(s) or letter(s) of the key choice in the answer blank.

Key Choices

A. Cardiac B. Smooth C. Skeletal


- | | |
|-------|--|
| _____ | 1. Involuntary |
| _____ | 2. Banded appearance |
| _____ | 3. Longitudinally and circularly arranged layers |
| _____ | 4. Dense connective tissue packaging |
| _____ | 5. Figure-8 packaging of the cells |
| _____ | 6. Coordinated activity to act as a pump |

Key Choices

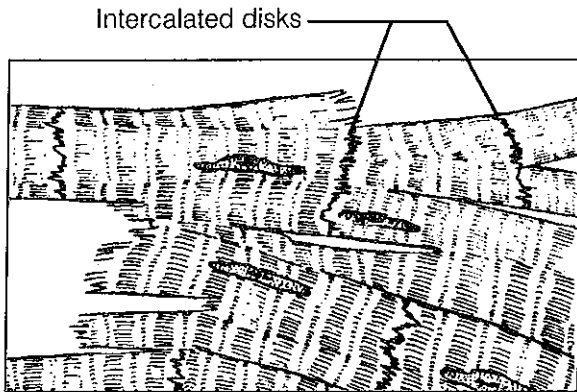
- A. Cardiac B. Smooth C. Skeletal

- _____ 7. Moves bones and the facial skin
 _____ 8. Referred to as the muscular system
 _____ 9. Voluntary

2. Identify the type of muscle in each of the illustrations in Figure 6–1. Color the diagrams as you wish.



A _____



B _____

Figure 6–1

3. Regarding the functions of muscle tissues, circle the term in each of the groupings that does not belong with the other terms.

1. Urine Foodstuffs Bones Smooth muscle
2. Heart Cardiac muscle Blood pump Promotes labor during birth
3. Excitability Response to a stimulus Contractility Action potential
4. Ability to shorten Contractility Pulls on bones Stretchability
5. Maintains posture Movement Promotes growth Generates heat

MICROSCOPIC ANATOMY OF SKELETAL MUSCLE

4. First, identify the structures in Column B by matching them with the descriptions in Column A. Enter the correct letters (or terms if desired) in the answer blanks. Then, select a different color for each of the terms in Column B that has a color-coding circle and color the structures in on Figure 6-2.

Column A	Column B
_____ 1. Connective tissue surrounding a fascicle	A. Endomysium <input type="radio"/>
_____ 2. Connective tissue ensheathing the entire muscle	B. Epimysium <input type="radio"/>
_____ 3. Contractile unit of muscle	C. Fascicle
_____ 4. A muscle cell	D. Fiber <input type="radio"/>
_____ 5. Thin connective tissue investing each muscle cell	E. Myofilament
_____ 6. Plasma membrane of the muscle cell	F. Myofibril <input type="radio"/>
_____ 7. A long, filamentous organelle found within muscle cells that has a banded appearance	G. Perimysium <input type="radio"/>
_____ 8. Actin- or myosin-containing structure	H. Sarcolemma
_____ 9. Cordlike extension of connective tissue beyond the muscle, serving to attach it to the bone	I. Sarcomere
_____ 10. A discrete bundle of muscle cells	J. Sarcoplasm
	K. Tendon <input type="radio"/>

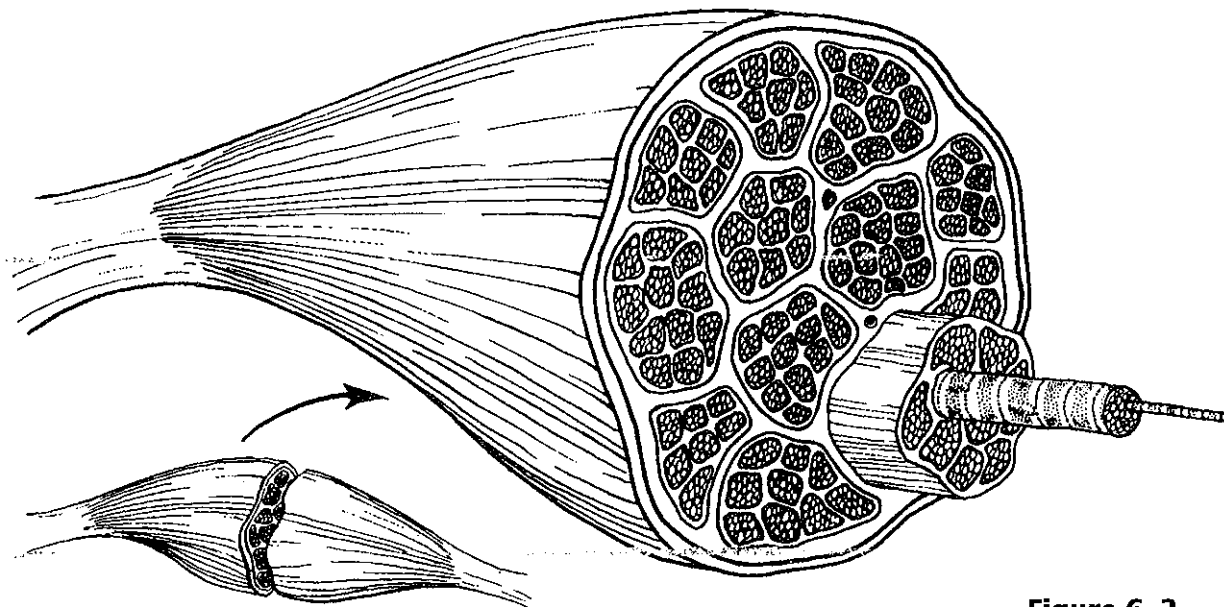


Figure 6-2

5. Figure 6-3 is a diagrammatic representation of a small portion of a relaxed muscle cell (bracket indicates the portion enlarged). First, select different colors for the structures listed below. Use them to color the coding circles and corresponding structures on Figure 6-3. Then bracket and label an A band, an I band, and a sarcomere. When you have finished, draw a contracted sarcomere in the space beneath the figure and label the same structures.

- Myosin
- Actin filaments
- Z line

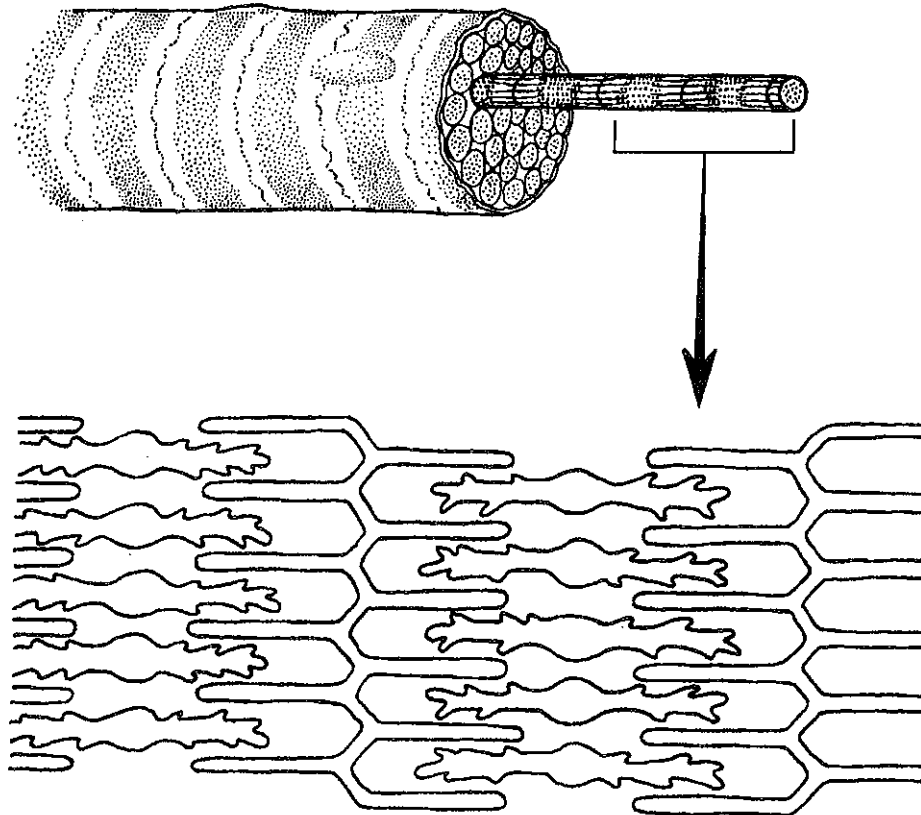


Figure 6-3

SKELETAL MUSCLE ACTIVITY

6. Complete the following statements relating to the neuromuscular junction. Insert the correct answers in the numbered answer blanks.

- _____ 1. A motor neuron and all of the skeletal muscle cells it stimulates is called a (1). The axon of each motor neuron
 _____ 2. has numerous endings called (2). The actual gap between an axonal ending and the muscle cell is called a (3).
 _____ 3. Within the axonal endings are many small vesicles containing a neurotransmitter substance called (4).
 _____ 4.
 _____ 5. When the (5) reaches the ends of the axon, the neurotransmitter is released, and it diffuses to the muscle cell membrane to combine with receptors there. Binding of the neurotransmitters with muscle membrane receptors causes the membrane to become permeable to sodium, resulting in the influx of sodium ions and (6) of the membrane. Then contraction of the muscle cell occurs.

7. Figure 6-4 shows the components of a neuromuscular junction. Identify the parts by coloring the coding circles and the corresponding structures in the diagram. Add small arrows to indicate the location of the ACh receptors and label appropriately.

- Mitochondrion T tubule Sarcomere
 Synaptic vesicles Synaptic cleft

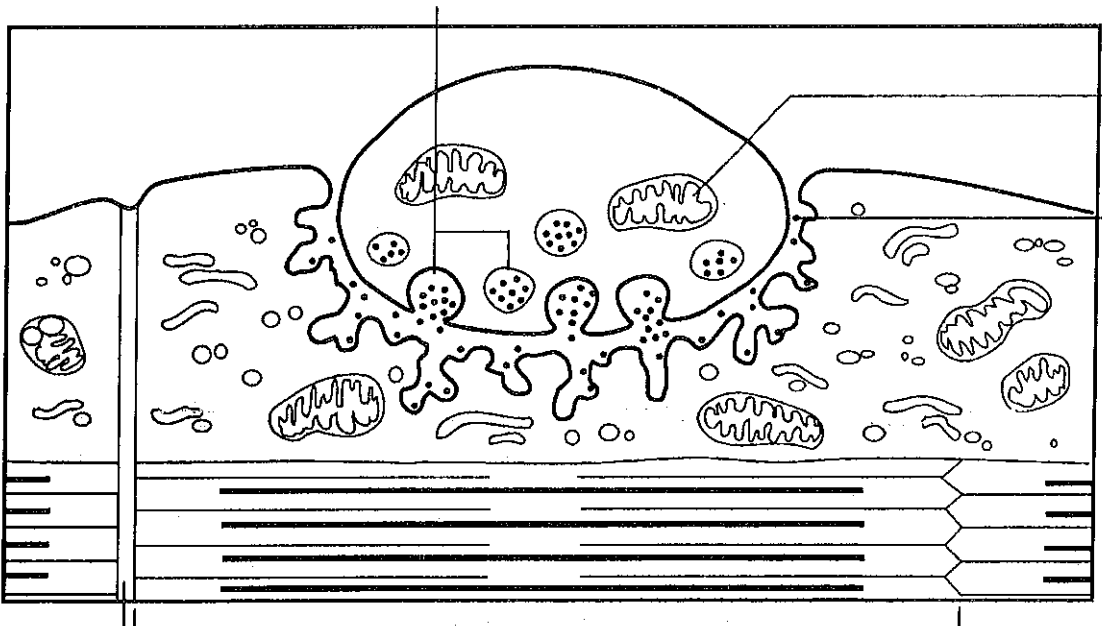


Figure 6-4

10. Complete the following statements by choosing the correct response from the key choices and entering the appropriate letter or term in the answer blanks.

Key Choices

- | | | |
|-------------------------|--------------------------|---------------------|
| A. Fatigue | E. Isometric contraction | I. Many motor units |
| B. Isotonic contraction | F. Whole muscle | J. Repolarization |
| C. Muscle cell | G. Tetanus | K. Depolarization |
| D. Muscle tone | H. Few motor units | |

- _____ 1. _____ is a continuous contraction that shows no evidence of relaxation.
- _____ 2. A(n) _____ is a contraction in which the muscle shortens and work is done.
- _____ 3. To accomplish a strong contraction, _____ are stimulated at a rapid rate.
- _____ 4. When a weak but smooth muscle contraction is desired, _____ are stimulated at a rapid rate.
- _____ 5. When a muscle is being stimulated but is not able to respond due to "oxygen debt," the condition is called _____.
- _____ 6. A(n) _____ is a contraction in which the muscle does not shorten but tension in the muscle keeps increasing.

11. The terms in the key refer to the three ways that muscle cells replenish their ATP supplies. Select the term(s) that best apply to the conditions described and insert the correct key letter(s) in the answer blanks.

Key Choices

- | | |
|-----------------------------------|------------------------|
| A. Coupled reaction of CP and ADP | C. Aerobic respiration |
| B. Anaerobic glycolysis | |

- _____ 1. Accompanied by lactic acid formation
- _____ 2. Supplies the highest ATP yield per glucose molecule
- _____ 3. Involves the simple transfer of a phosphate group
- _____ 4. Requires no oxygen
- _____ 5. The slowest ATP regeneration process
- _____ 6. Produces carbon dioxide and water
- _____ 7. The energy mechanism used in the second hour of running in a marathon
- _____ 8. Used when the oxygen supply is inadequate over time
- _____ 9. Good for a sprint

12. Briefly describe how you can tell when you are repaying the oxygen debt.

13. Which of the following occur within a muscle cell during oxygen debt? Place a check (✓) by the correct choices.

- | | | | |
|-------|--------------------------|-------|-----------------------------|
| _____ | 1. Decreased ATP | _____ | 5. Increased oxygen |
| _____ | 2. Increased ATP | _____ | 6. Decreased carbon dioxide |
| _____ | 3. Increased lactic acid | _____ | 7. Increased carbon dioxide |
| _____ | 4. Decreased oxygen | _____ | 8. Increased glucose |

MUSCLE MOVEMENTS, TYPES, AND NAMES

14. Relative to general terminology concerning muscle activity, first label the following structures on Figure 6-5: insertion, origin, tendon, resting muscle, and contracting muscle. Next, identify the two structures named below by choosing different colors for the coding circles and the corresponding structures in the figure.

- Movable bone
- Immovable bone

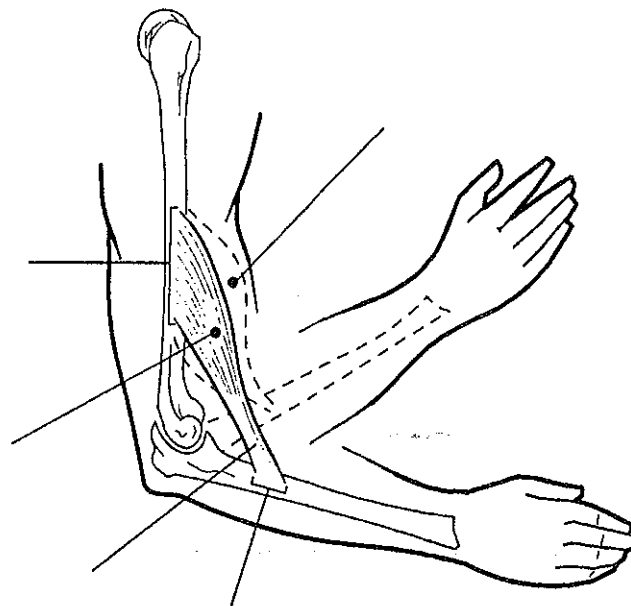


Figure 6-5

15. Complete the following statements. Insert your answers in the answer blanks.

- _____ 1. Standing on your toes as in ballet is (1) of the foot. Walking on your heels is (2).
- _____ 2. _____
- _____ 3. Winding up for a pitch (as in baseball) can properly be called (3). To keep your seat when riding a horse, the tendency is to (4) your thighs.
- _____ 4. _____
- _____ 5. In running, the action at the hip joint is (5) in reference to the leg moving forward and (6) in reference to the leg in the posterior position. When kicking a football, the action at the knee is (7). In climbing stairs, the hip and knee of the forward leg are both (8). You have just touched your chin to your chest; this is (9) of the neck.
- _____ 6. _____
- _____ 7. _____
- _____ 8. Using a screwdriver with a straight arm requires (10) of the arm. Consider all the movements of which the arm is capable.
- _____ 9. One often used for strengthening all the upper arm and shoulder muscles is (11).
- _____ 10. _____
- _____ 11. Moving the head to signify "no" is (12). Action that moves the distal end of the radius across the ulna is (13). Raising the arms laterally away from the body is called (14) of the arms.
- _____ 12. _____
- _____ 13. _____
- _____ 14. _____

16. The terms provided in the key are often used to describe the manner in which muscles interact with other muscles. Select the key terms that apply to the following definitions and insert the correct letter or term in the answer blanks.

Key Choices

- A. Antagonist B. Fixator C. Prime mover D. Synergist

- _____ 1. Agonist
- _____ 2. Postural muscles for the most part
- _____ 3. Stabilizes a joint so that the prime mover can act at more distal joints
- _____ 4. Performs the same movement as the prime mover
- _____ 5. Reverses and/or opposes the action of a prime mover
- _____ 6. Immobilizes the origin of a prime mover

17. Several criteria are applied to the naming of muscles. These are provided in Column B. Identify which criteria pertain to the muscles listed in Column A and enter the correct letter(s) in the answer blank.

Column A	Column B
_____ 1. Gluteus maximus	A. Action of the muscle
_____ 2. Adductor magnus	B. Shape of the muscle
_____ 3. Biceps femoris	C. Location of the muscle's origin and/or insertion
_____ 4. Abdominis transversus	D. Number of origins
_____ 5. Extensor carpi ulnaris	E. Location of muscle relative to a bone or body region
_____ 6. Trapezius	F. Direction in which the muscle fibers run relative to some imaginary line
_____ 7. Rectus femoris	G. Relative size of the muscle
_____ 8. External oblique	

GROSS ANATOMY OF THE SKELETAL MUSCLES

Muscles of the Head

18. Identify the major muscles described in Column A by choosing a response from Column B. Enter the correct letter in the answer blank. Select a different color for each muscle described and color in the coding circle and corresponding muscle on Figure 6-6.

Column A	Column B
<input type="radio"/> _____ 1. Used in smiling	A. Buccinator
<input type="radio"/> _____ 2. Used to suck in your cheeks	B. Frontalis
<input type="radio"/> _____ 3. Used in winking	C. Masseter
<input type="radio"/> _____ 4. Used to form the horizontal frown crease on the forehead	D. Orbicularis oculi
<input type="radio"/> _____ 5. The "kissing" muscle	E. Orbicularis oris
<input type="radio"/> _____ 6. Prime mover of jaw closure	F. Sternocleidomastoid
<input type="radio"/> _____ 7. Synergist muscle for jaw closure	G. Temporalis
<input type="radio"/> _____ 8. Prime mover of head flexion; a two-headed muscle	H. Trapezius
	I. Zygomaticus

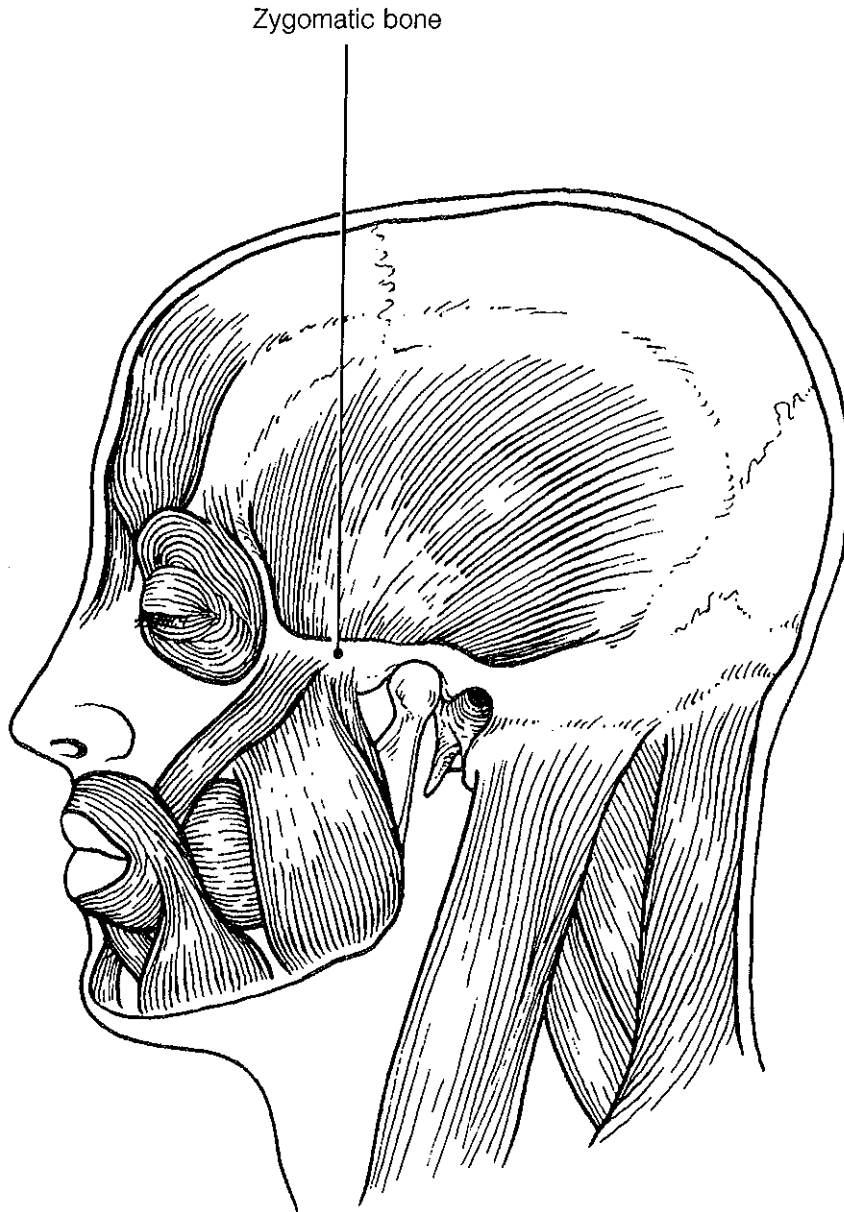


Figure 6-6

Muscles of the Trunk

19. Identify the anterior trunk muscles described in Column A by choosing a response from Column B. Enter the correct letter in the answer blank. Then, for each muscle description that has a color coding circle, select a different color to color the coding circle and corresponding muscle on Figure 6-7.

Column A	Column B
<input type="radio"/> _____ 1. The name means "straight muscle of the abdomen"	A. Deltoid
<input type="radio"/> _____ 2. Prime mover for shoulder flexion and adduction	B. Diaphragm
<input type="radio"/> _____ 3. Prime mover for shoulder abduction	C. External intercostal
<input type="radio"/> _____ 4. Part of the abdominal girdle; forms the external lateral walls of the abdomen	D. External oblique
<input type="radio"/> _____ 5. Acting alone, each muscle of this pair turns the head toward the opposite shoulder	E. Internal intercostal
_____ 6. and 7. Besides the two abdominal muscles (pairs) named above, two muscle pairs that help form the natural abdominal girdle	F. Internal oblique
_____ 8. Deep muscles of the thorax that promote the inspiratory phase of breathing	G. Latissimus dorsi
_____ 9. An unpaired muscle that acts with the muscles named immediately above to accomplish inspiration	H. Pectoralis major
	I. Rectus abdominis
	J. Sternocleidomastoid
	K. Transversus abdominis

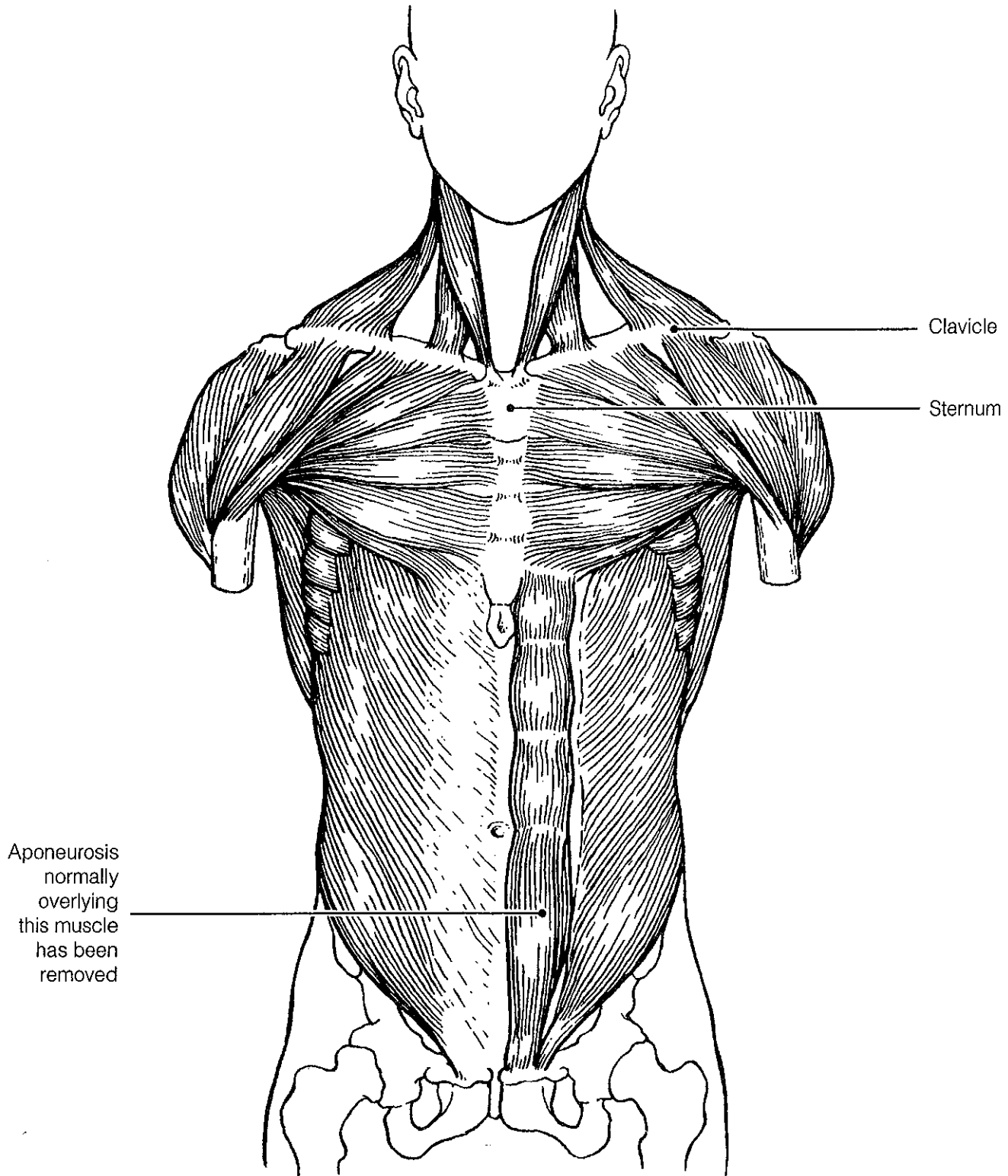


Figure 6-7

20. Identify the posterior trunk muscles described in Column A by choosing a response from Column B. Enter the correct letter in the answer blank. Select a different color for each muscle description with a coding circle and color the coding circles and corresponding muscles on Figure 6–8.

Column A

- _____ 1. Muscle that allows you to shrug your shoulders or extend your head
- _____ 2. Muscle that adducts the shoulder and causes extension of the shoulder joint
- _____ 3. Shoulder muscle that is the antagonist of the muscle just described
- _____ 4. Prime mover of back extension; a deep composite muscle consisting of three columns

Column B

- A. Deltoid
- B. Erector spinae
- C. External oblique
- D. Gluteus maximus
- E. Latissimus dorsi
- F. Pectoralis major
- G. Rectus abdominis
- H. Trapezius

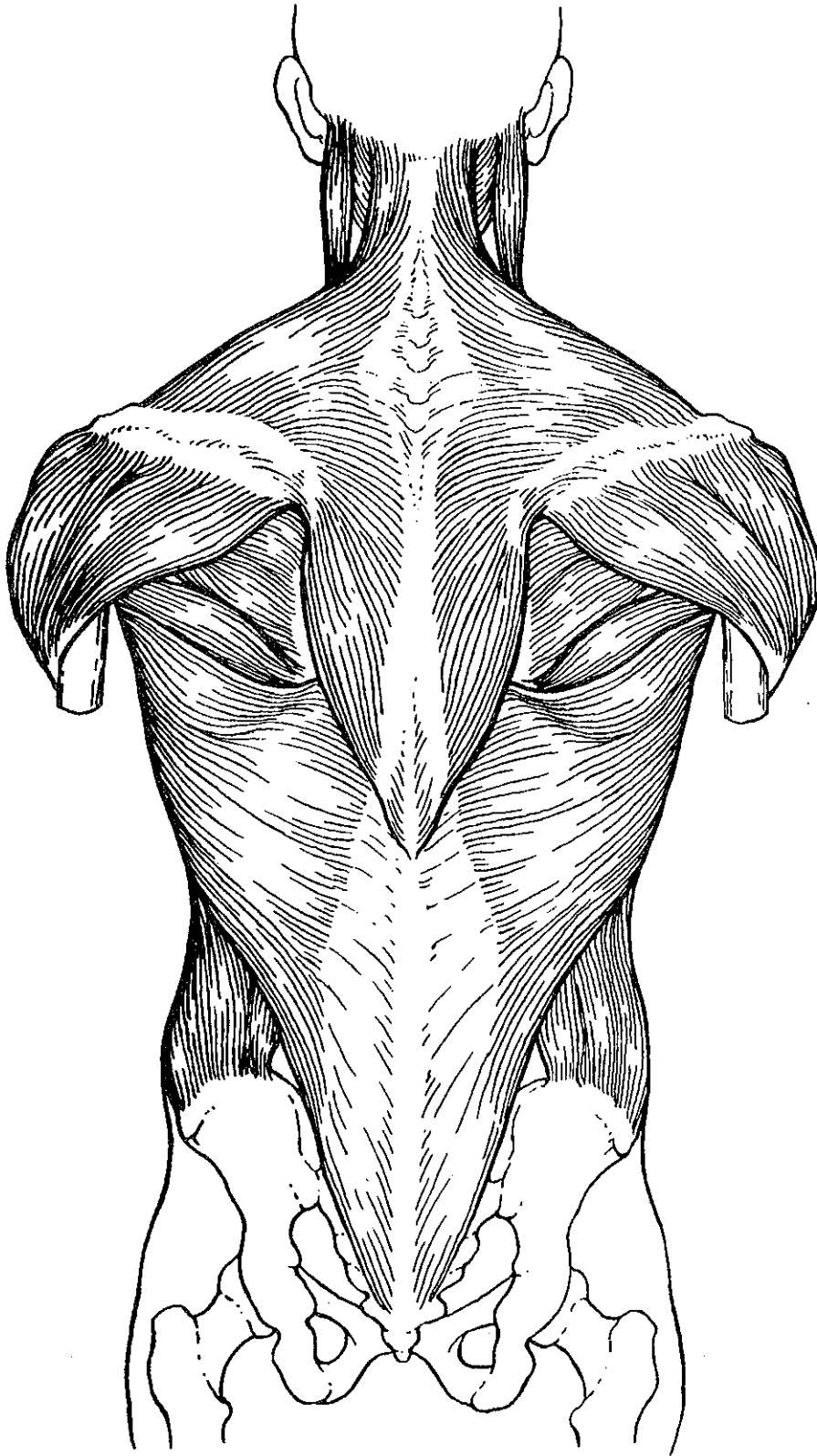


Figure 6-8

Muscles of the Hip, Thigh, and Leg

21. Identify the muscles described in Column A by choosing a response from Column B. Enter the correct letter in the answer blank. Select a different color for each muscle description provided with a color-coding circle, and use it to color the coding circles and corresponding muscles on Figure 6–9. Complete the illustration by labeling those muscles provided with leader lines.

Column A		Column B
_____	1. Hip flexor, deep in pelvis; a composite of two muscles	A. Adductors
<input type="radio"/> _____	2. Used to extend the hip when climbing stairs	B. Biceps femoris
<input type="radio"/> _____	3. “Toe dancer’s” muscle; a two-bellied muscle of the calf	C. Gastrocnemius
<input type="radio"/> _____	4. Inverts and dorsiflexes the foot	D. Gluteus maximus
<input type="radio"/> _____	5. Muscle group that allows you to draw your legs to the midline of your body, as when standing at attention	E. Gluteus medius
<input type="radio"/> _____	6. Muscle group that extends the knee	F. Hamstrings
<input type="radio"/> _____	7. Muscle group that extends the thigh and flexes the knee	G. Iliopsoas
<input type="radio"/> _____	8. Smaller hip muscle commonly used as an injection site	H. Peroneus muscles
<input type="radio"/> _____	9. Muscle group of the lateral leg; plantar flex and evert the foot	I. Quadriceps
<input type="radio"/> _____	10. Strap-like muscle that is a weak thigh flexor; the “tailor’s muscle”	J. Rectus femoris
		K. Sartorius
		L. Semimembranosus
		M. Semitendinosus
		N. Tibialis anterior
		O. Vastus intermedius
		P. Vastus lateralis
		Q. Vastus medialis

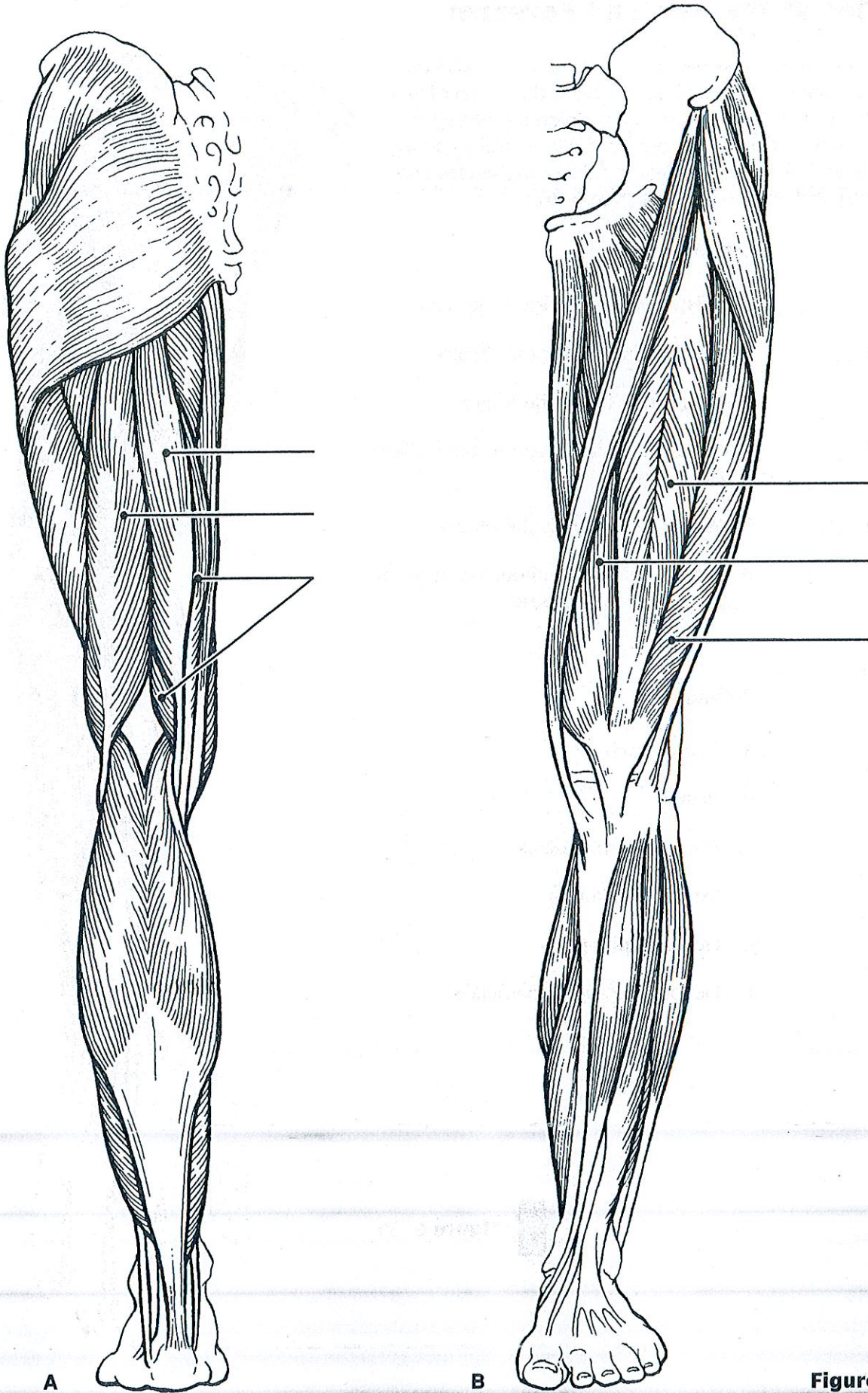


Figure 6-9

Muscles of the Arm and Forearm

22. Identify the muscles described in Column A by choosing a response from Column B. Enter the correct letter in the answer blank. Then select different colors for each muscle description provided with a color-coding circle and use them to color in the coding circles and corresponding muscles on Figure 6–10.

Column A

- _____ 1. Wrist flexor that follows the ulna
- _____ 2. Muscle that extends the fingers
- _____ 3. Muscle that flexes the fingers
- _____ 4. Muscle that allows you to bend (flex) the elbow
- _____ 5. Muscle that extends the elbow
- _____ 6. Powerful shoulder abductor, used to raise the arm overhead

Column B

- A. Biceps brachii
- B. Deltoid
- C. Extensor carpi radialis
- D. Extensor digitorum
- E. Flexor carpi ulnaris
- F. Flexor digitorum superficialis
- G. Triceps brachii

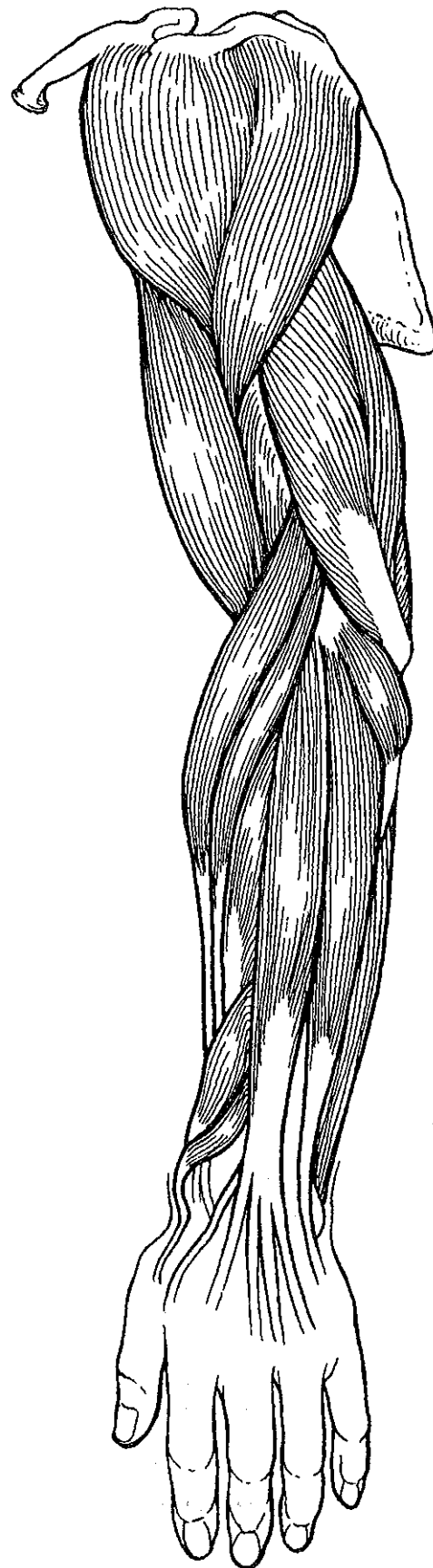

Figure 6–10

General Body Muscle Review

23. Complete the following statements describing muscles. Insert the correct answers in the answer blanks.

- _____ 1. Three muscles— (1), (2), and (3)—are commonly used for intramuscular injections in adults.
- _____ 2. _____
- _____ 3. The insertion tendon of the (4) group contains a large sesamoid bone, the patella.
- _____ 4. The triceps surae insert in common into the (5) tendon.
- _____ 5. The bulk of the tissue of a muscle tends to lie (6) to the part of the body it causes to move.
- _____ 6. _____
- _____ 7. The extrinsic muscles of the hand originate on the (7).
- _____ 8. Most flexor muscles are located on the (8) aspect of the body; most extensors are located (9). An exception to this generalization is the extensor-flexor musculature of the (10).
- _____ 9. _____
- _____ 10. The pectoralis major and deltoid muscles act synergistically to (11) the arm.
- _____ 11.

24. Circle the term that does not belong in each of the following groupings.

- | | | | | |
|---------------------|------------------|--------------------|----------------------|------------|
| 1. Vastus lateralis | Vastus medialis | Knee extension | Biceps femoris | |
| 2. Latissimus dorsi | Pectoralis major | Shoulder adduction | Antagonists | |
| 3. Buccinator | Frontalis | Masseter | Mastication | Temporalis |
| 4. Vastus medialis | Rectus femoris | Iliacus | Origin on coxal bone | |

25. Identify the numbered muscles in Figure 6–11 by placing the numbers in the blanks next to the following muscle names. Then select a different color for each muscle provided with a color-coding circle and color the coding circle and corresponding muscle in Figure 6–11.

- _____ 1. Orbicularis oris
- _____ 2. Pectoralis major
- _____ 3. External oblique
- _____ 4. Sternocleidomastoid
- _____ 5. Biceps brachii
- _____ 6. Deltoid
- _____ 7. Vastus lateralis
- _____ 8. Frontalis
- _____ 9. Rectus femoris
- _____ 10. Sartorius
- _____ 11. Gracilis
- _____ 12. Adductor group
- _____ 13. Peroneus longus
- _____ 14. Temporalis
- _____ 15. Orbicularis oculi
- _____ 16. Zygomaticus
- _____ 17. Masseter
- _____ 18. Vastus medialis
- _____ 19. Tibialis anterior
- _____ 20. Transversus abdominus
- _____ 21. Tensor fascia lata
- _____ 22. Rectus abdominis

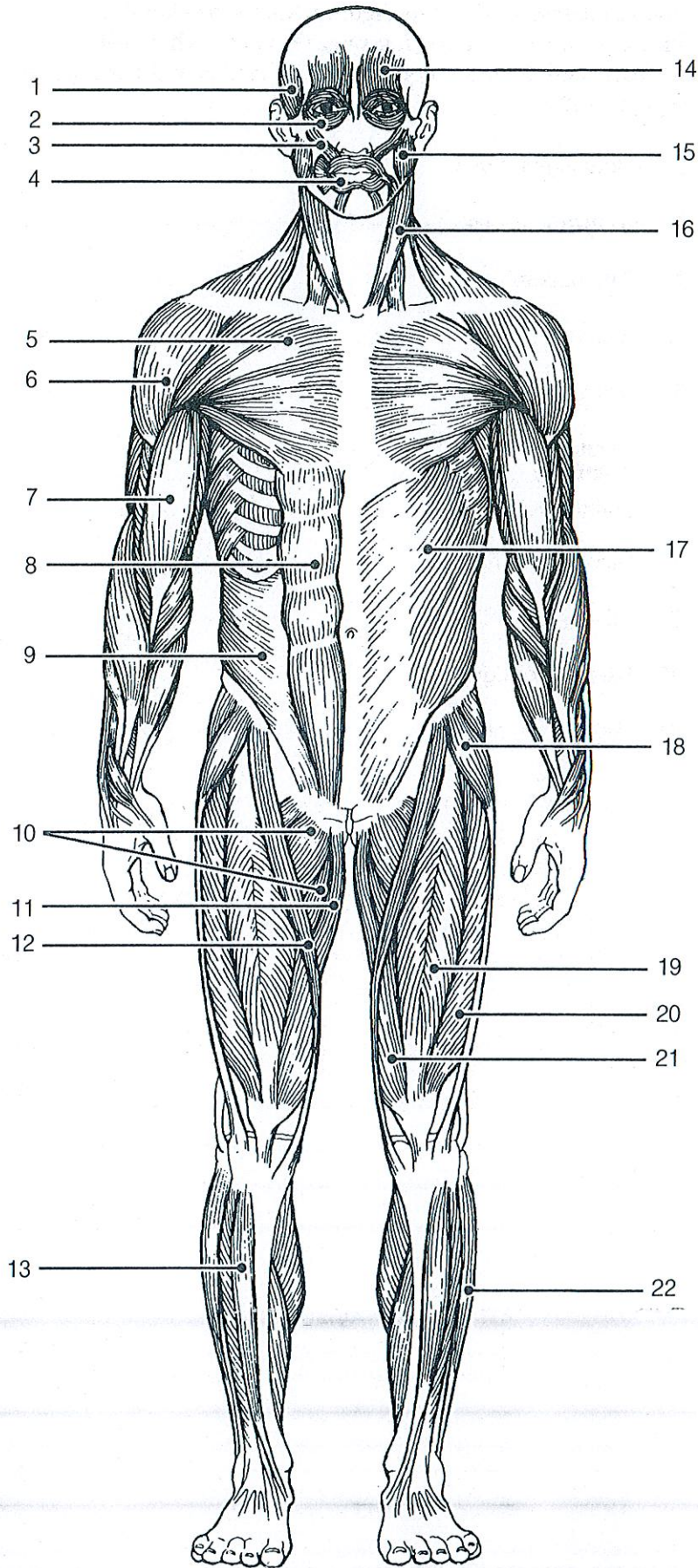


Figure 6-11

26. Identify each of the numbered muscles in Figure 6–12 by placing the numbers in the blanks next to the following muscle names. Then select different colors for each muscle and color the coding circles and corresponding muscles on Figure 6–12.

- _____ 1. Gluteus maximus
- _____ 2. Adductor muscle
- _____ 3. Gastrocnemius
- _____ 4. Latissimus dorsi
- _____ 5. Deltoid
- _____ 6. Semitendinosus
- _____ 7. Trapezius
- _____ 8. Biceps femoris
- _____ 9. Triceps brachii
- _____ 10. External oblique
- _____ 11. Gluteus medius

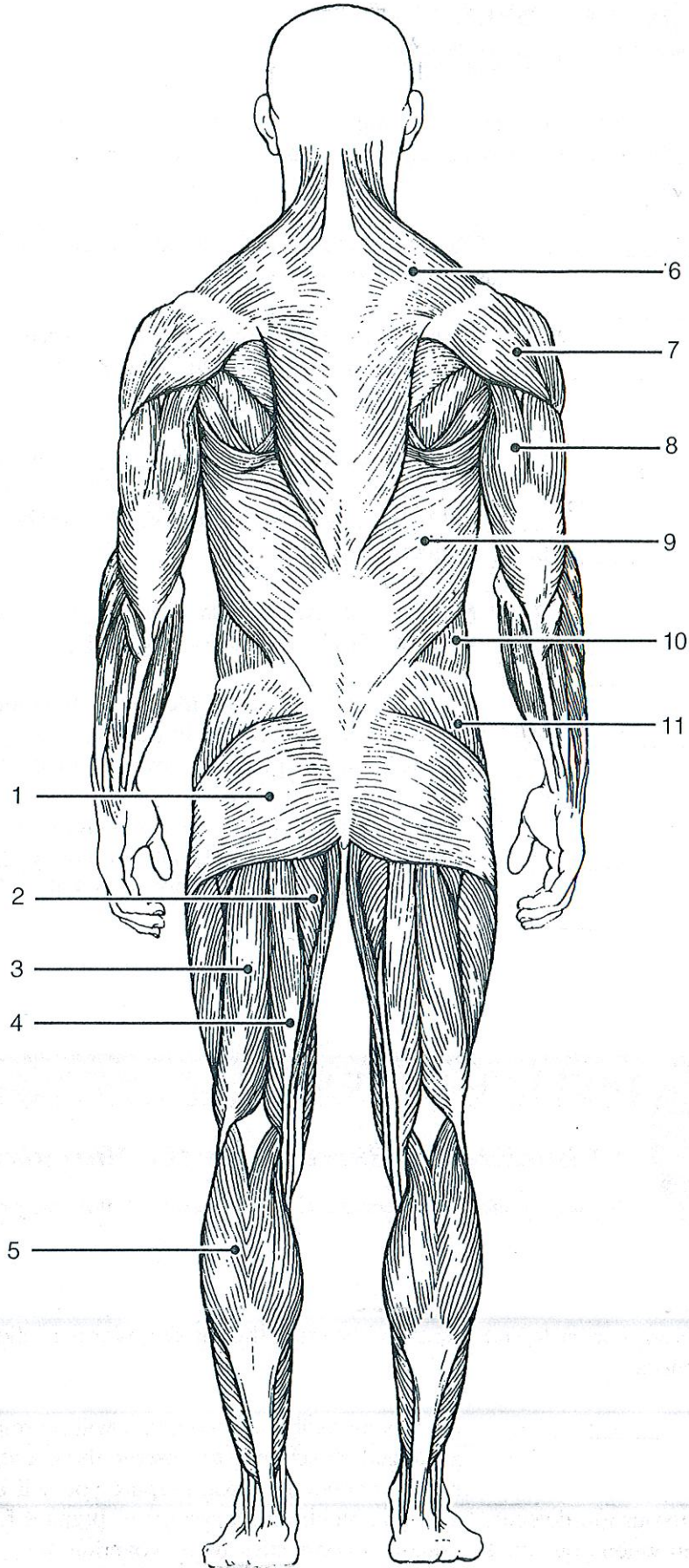
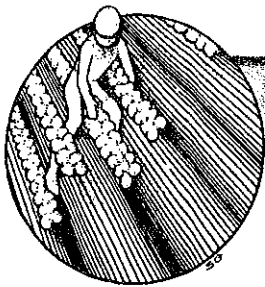


Figure 6-12

DEVELOPMENTAL ASPECTS OF THE MUSCULAR SYSTEM

27. Complete the following statements concerning the embryonic development of muscles and their functioning throughout life. Insert your answers in the answer blanks.

- _____ 1. The first movement of the baby detected by the mother-to-be is called the (1).
- _____ 2.
- _____ 3. An important congenital muscular disease that results in the degeneration of the skeletal muscles by young adulthood is called (2).
- _____ 4.
- _____ 5. A baby's control over muscles progresses in a (3) direction as well as a (4) direction. In addition, (5) muscular control (that is, waving of the arms) occurs before (6) control (pincer grasp) does.
- _____ 6.
- _____ 7. Muscles will ordinarily stay healthy if they are (7) regularly; without normal stimulation they (8).
- _____ 8.
- _____ 9. (9) is a disease of the muscles, which results from some problem with the stimulation of muscles by acetylcholine. The muscles become progressively weaker in this disease.
- _____ 10.
- _____ 11. With age, our skeletal muscles decrease in mass; this leads to a decrease in body (10) and in muscle (11). Muscle tissue that is lost is replaced by noncontractile (12) tissue.
- _____ 12.



INCREDIBLE JOURNEY

A Visualization Exercise for the Muscular System

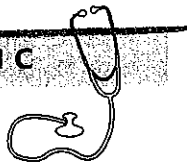
As you straddle this structure, you wonder what is happening.

28. Where necessary, complete statements by inserting the missing words in the numbered spaces.

- _____ 1. On this incredible journey, you will be miniaturized and enter a skeletal muscle cell to observe the events that occur during muscle contraction. You prepare yourself by donning a wet suit and charging your ion detector. Then you climb into a syringe to prepare for injection. Your journey will begin when you see the gleaming connective tissue covering, the (1) of a single muscle cell. Once injected, you monitor your descent through the epidermis and subcutaneous tissue. When you reach the muscle cell surface, you see that it is punctuated with pits at relatively

- _____ 2. regular intervals. Looking into the darkness and off in the distance, you can see a leash of fibers ending close to a number of muscle cells. Since all of these fibers must be from the same motor neuron, this functional unit is obviously a (2).
- _____ 3. You approach the fiber ending on your muscle cell and scrutinize the (3) junction there. As you examine the junction, minute fluid droplets leave the nerve ending and attach to doughnut-shaped receptors on the muscle cell membrane.
- _____ 4. This substance released by the nerve ending must be (4).
- _____ 5. Then, as a glow falls over the landscape, your ion detector indicates ions are disappearing from the muscle cell exterior and entering the muscle pits. The needle drops from high to low as the (5) ions enter the pits from the watery fluid outside. You should have expected this, since these ions must enter to depolarize the muscle cells and start the (6).
- _____ 6. Next, you begin to explore one of the surface pits. As the muscle jerks into action, you topple deep into the pit.
- _____ 7. Sparkling electricity lights up the wall on all sides. You grasp for a handhold. Finally successful, you pull yourself laterally into the interior of the muscle cell and walk carefully along what seems to be a log. Then, once again, you notice an eerie glow as your ion detector reports that (7) ions are entering the cytoplasm rapidly. The “log” you are walking on “comes to life” and begins to slide briskly in one direction. Unable to keep your balance, you fall. As you straddle this structure, you wonder what is happening. On all sides, cylindrical structures—such as the one you are astride—are moving past other similar but larger structures. Suddenly you remember, these are the (8) myofilaments that slide past the (9) myofilaments during muscle contraction.
- _____ 8. Seconds later, the forward movement ends, and you begin to journey smoothly in the opposite direction. The ion detector now indicates low (10) ion levels. Since you cannot ascend the smooth walls of one of the entry pits, you climb from one myofilament to another to reach the underside of the sarcolemma. Then you travel laterally to enter a pit close to the surface and climb out onto the cell surface. Your journey is completed, and you prepare to leave your host once again.

AT THE CLINIC



29. Out of control during a temper tantrum, Malcolm smashed his fist through a glass door. Several tendons were sliced through at the anterior wrist. What movements are likely to be lost if tendon repair is not possible?

30. During an overambitious workout, a high school athlete pulls some muscles by forcing his knee into extension when his hip is already fully flexed. What muscles does he pull?

31. An emergency appendectomy is performed on Mr. Geiger. The incision was made at the lateral edge of the right iliac abdominopelvic region. Was his rectus abdominis cut?

32. Susan, a massage therapist, was giving Mr. Graves a backrub. What two broad superficial muscles of the back were receiving the “bulk” of her attention?

33. Mrs. Sanchez says that her 6-year-old son seems to be unusually clumsy and tires easily. The doctor notices that his calf muscles appear to be normal in size. If anything, they seem a bit enlarged rather than wasted. For what condition must the boy be checked? What is the prognosis?

34. People with chronic back pain occasionally get relief from a tummy tuck. How does this help?

35. Drugs are used to relax muscles during major surgery. Which of the two chemicals described next would make the best muscle relaxant and why? Chemical A binds with and blocks ACh receptors on muscle cells. Chemical B floods the sarcoplasm of muscle cells with calcium ions.